

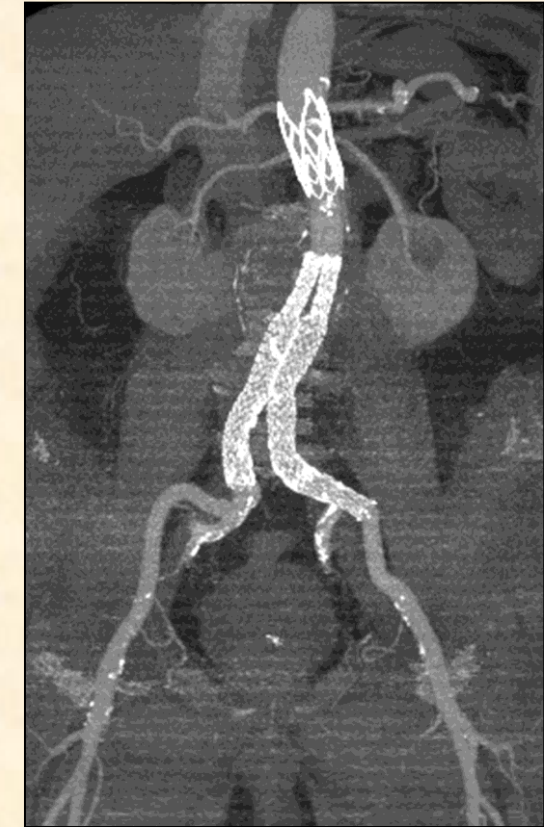
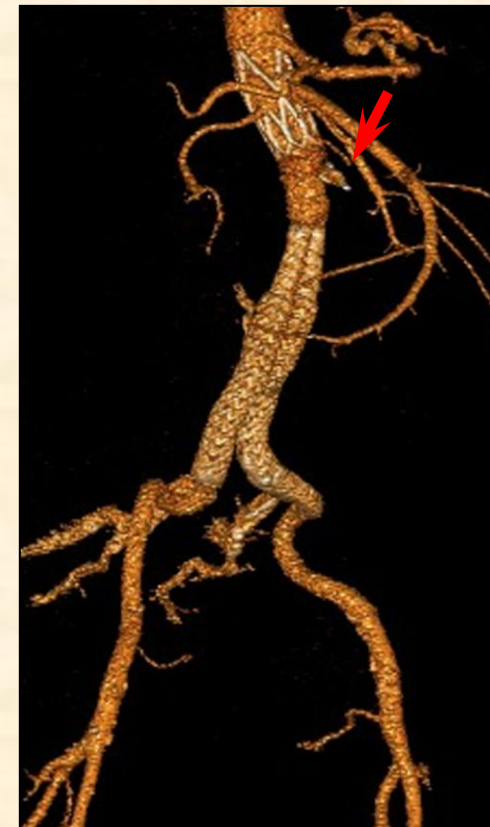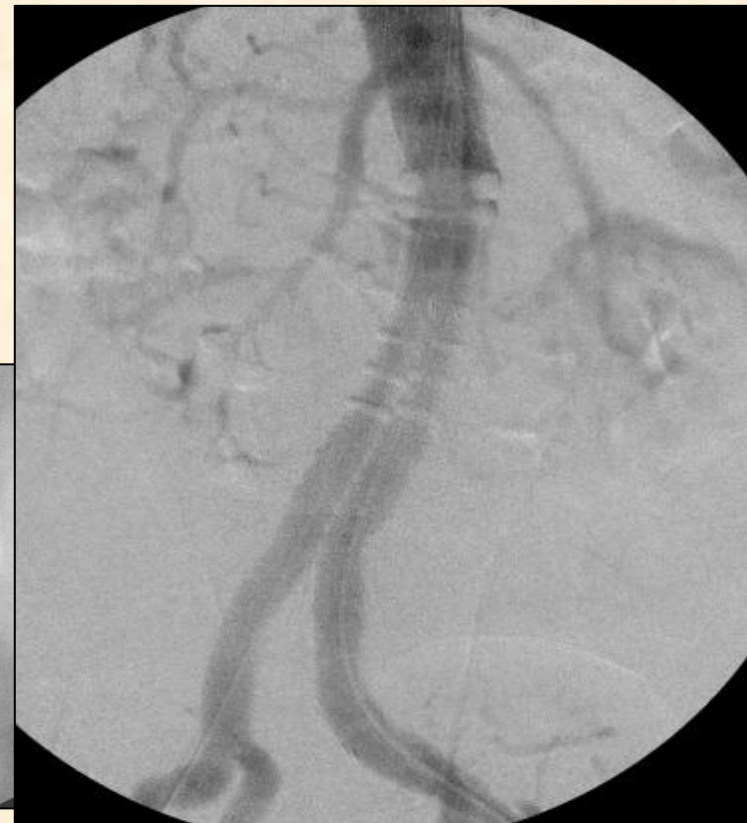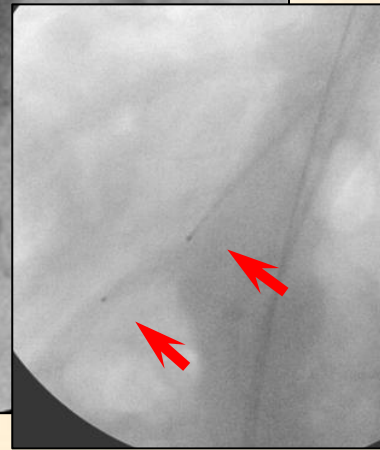


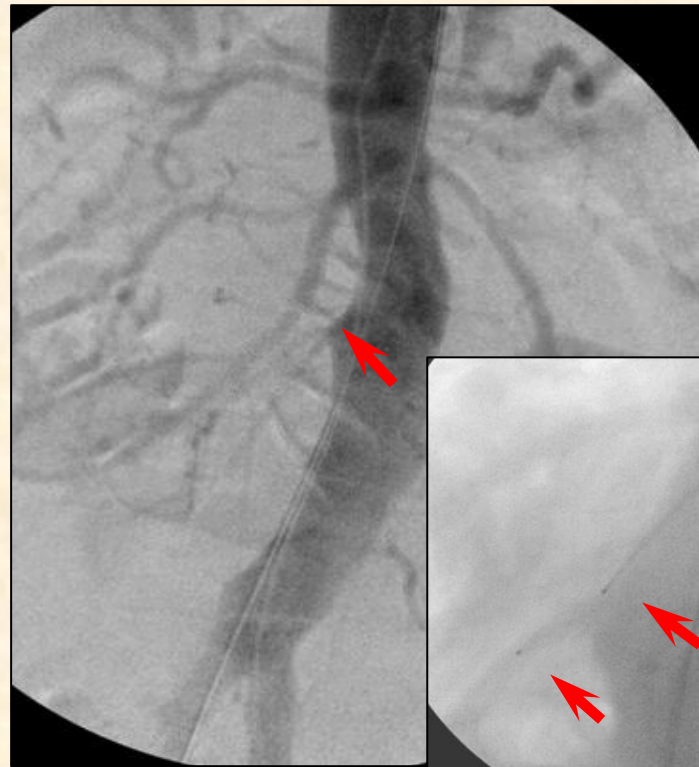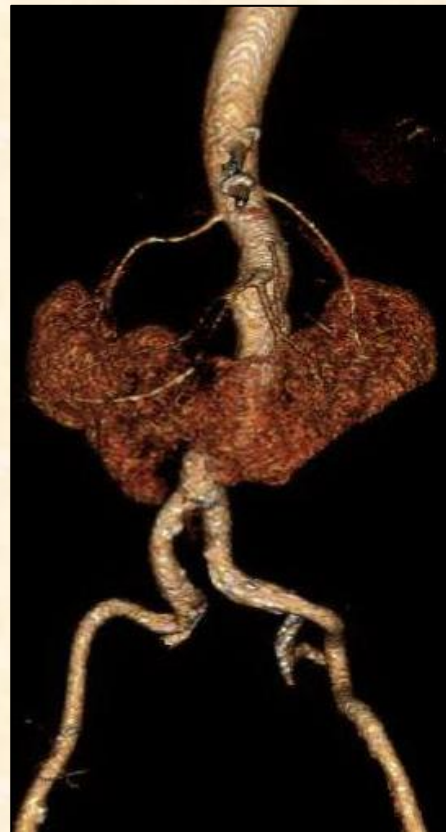PEVAR in a patient with a horseshoe kidney using a stent-graft the Ovation Prime

Frantsevich A.M.^{1,2}, MD; Tsygankov V.N.^{1,2}, MD, PhD; Pokrovsky A.V.¹, MD, PhD, professor, academician of RAS

1. Institute of Surgery named after A.V. Vishnevsky under the Russian Federation Ministry of Public Health

2. The First Sechenov Moscow State Medical University under the Russian Federation Ministry of Public Health



Presentation

Patient with a horseshoe kidney presents for follow-up 6 months following completely percutaneous endoprosthesis of infrarenal abdominal aorta using extra-low profile Ovation Prime stent-graft and occlusion of the arteria isthmus by Amplatzer Plug IV.

Cardiovascular Risk Factors

- Hypertension
- Hyperlipidemia
- Hyperuricemia
- Obesity IV
- Tobacco use 50 years
- CABG 2014

Laboratory values

	Crea
before	150 mcmol/l
after	114 mcmol/l
	Urea
before	9,2 mmol/l
after	7,0 mmol/l

