

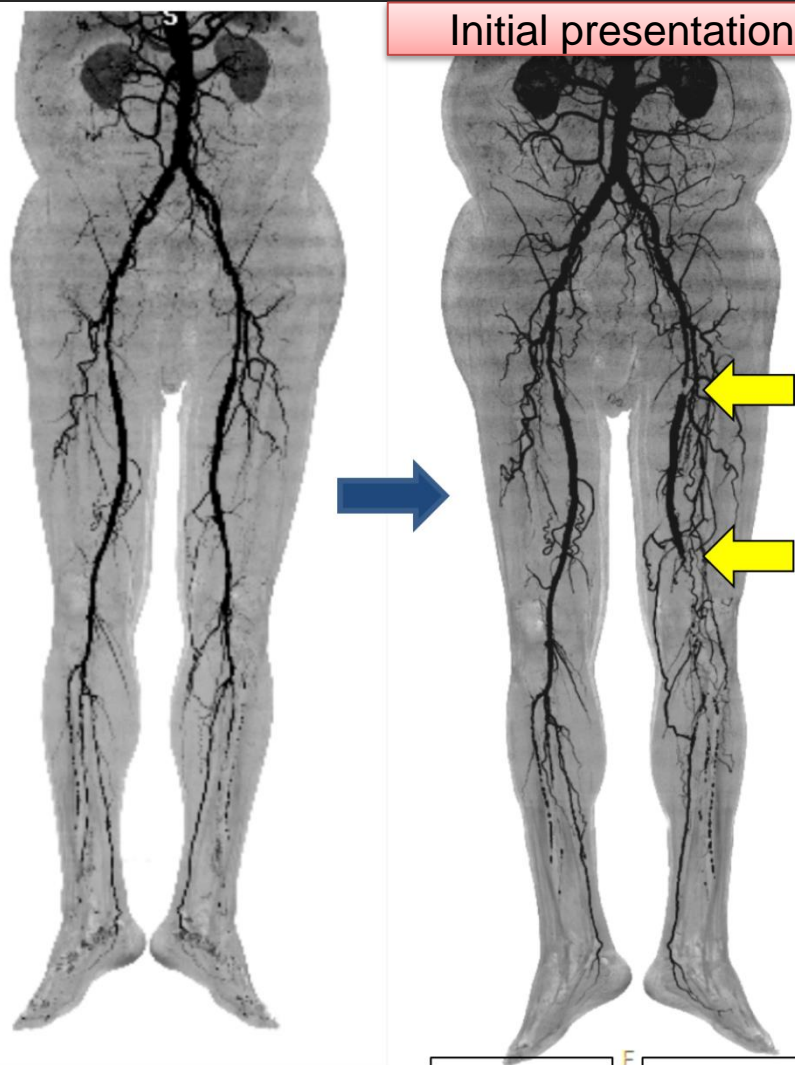
## Successful revascularization for chronic thrombotic occlusion of superficial femoral artery in-stent restenosis co-existing below-the-knee disease using multidisciplinary strategy

Jun-Won Lee, Seung-Hwan Lee, Yonsei University Wonju College of Medicine, Wonju, Korea

### Patient history

- 82-year old, Female
- Left leg pain (Fontaine class IIb)
- Feb. 2008 : PAOD
  - Lt SFA : SMART control 6/100, 8/100
  - Rt SFA : SMART control 6/100, 8/100
- Risk factors : Hypertension, DM, CKD

### Initial presentation

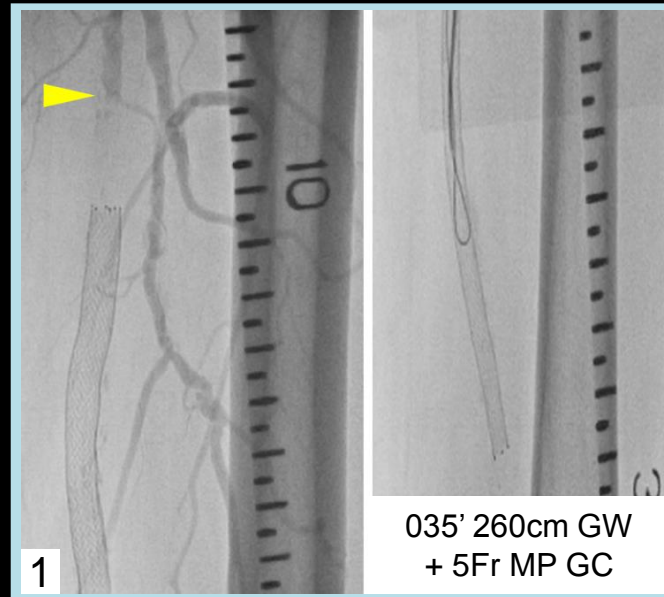


ABI 0.86    ABI 0.46

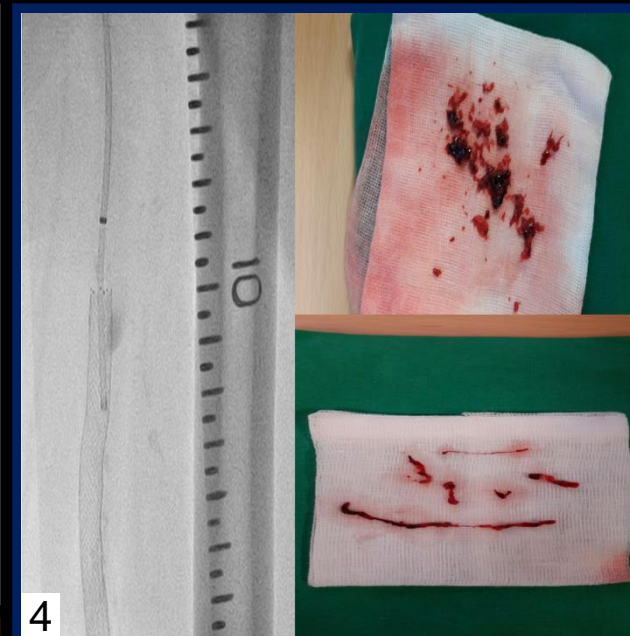
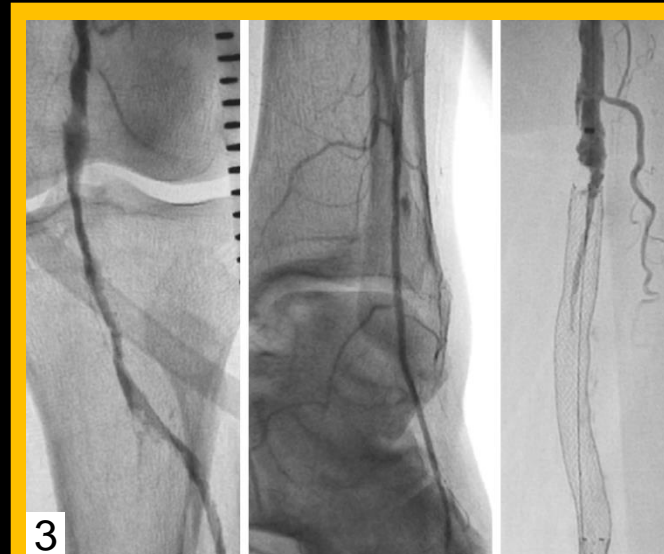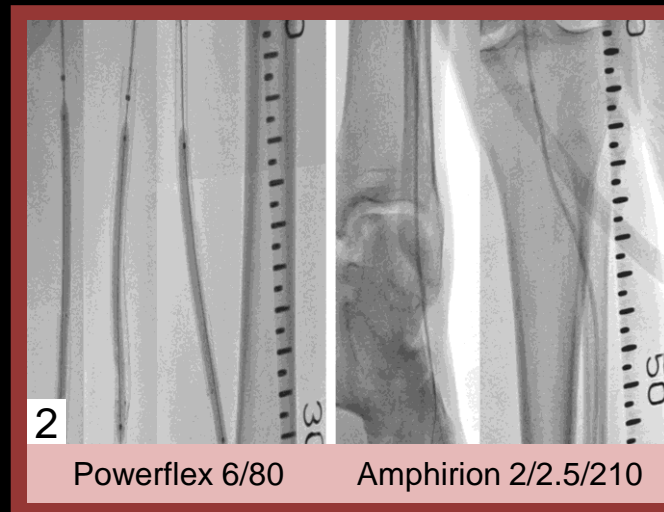
2010.6.4

2015.3.30

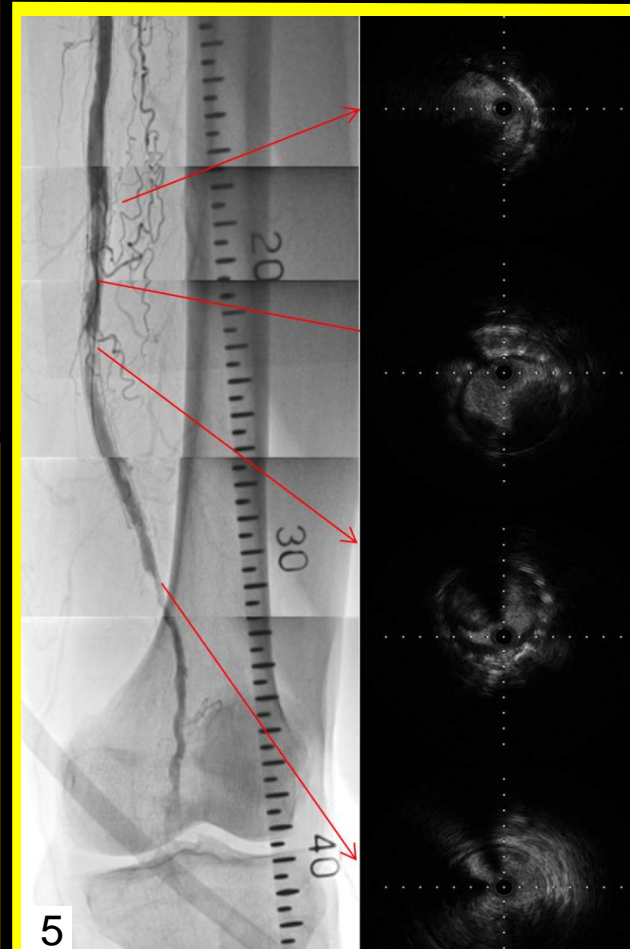
Disclosure : Nothing to disclose



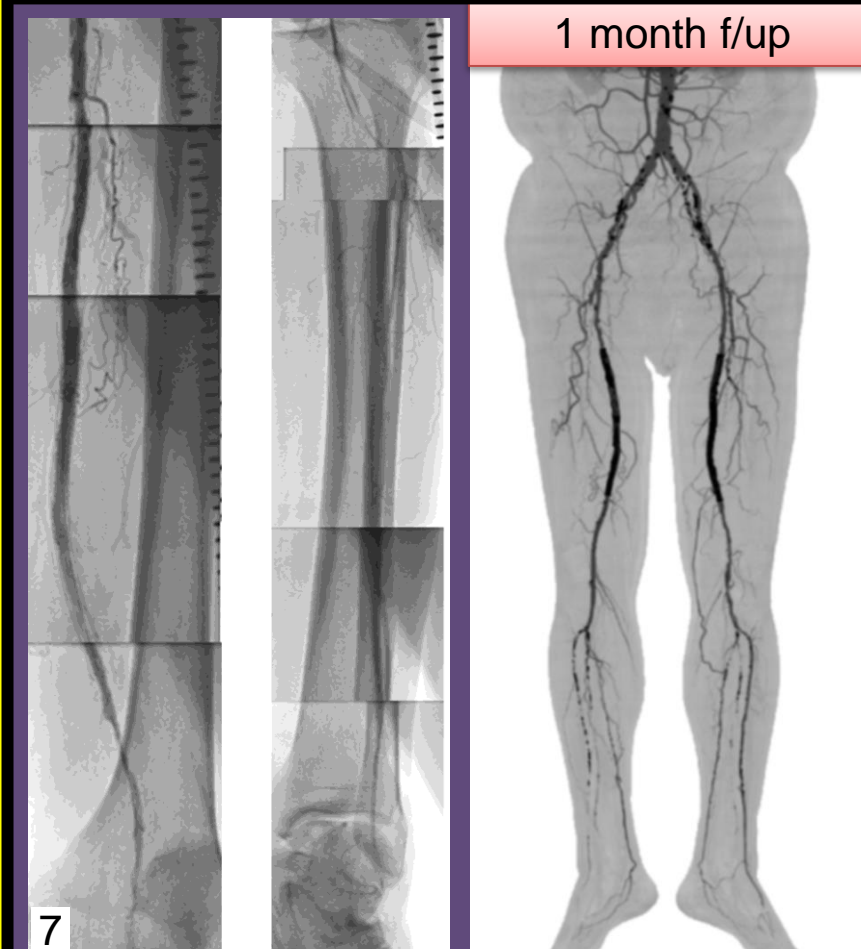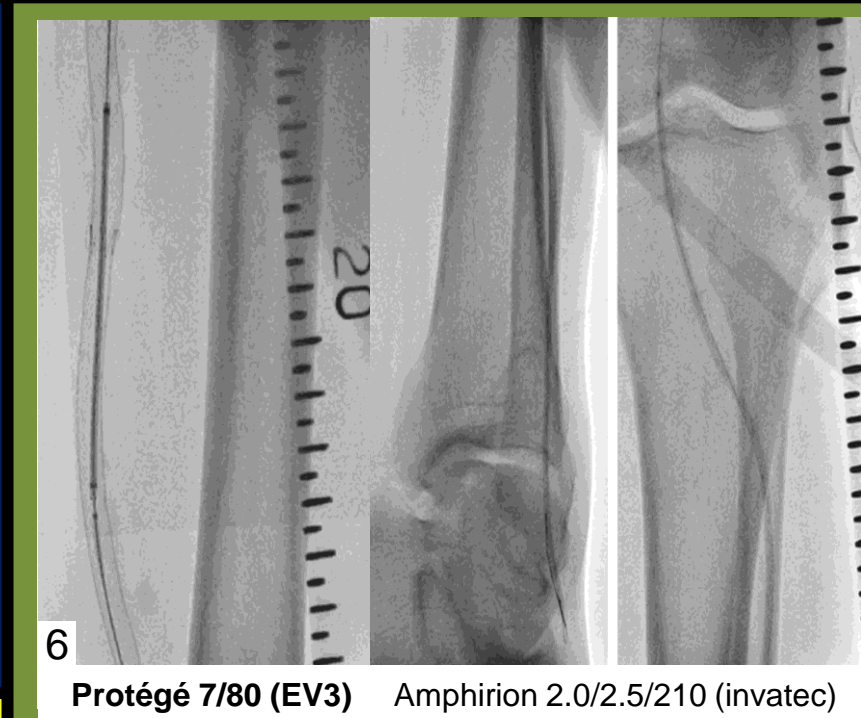035' 260cm GW + 5Fr MP GC



Thrombus aspiration : 6Fr MP GC



Chronic organized thrombi underlying neoatherosclerosis



### 1 month f/up

ABI 0.89    ABI 0.93

Urokinase 60,000 IU