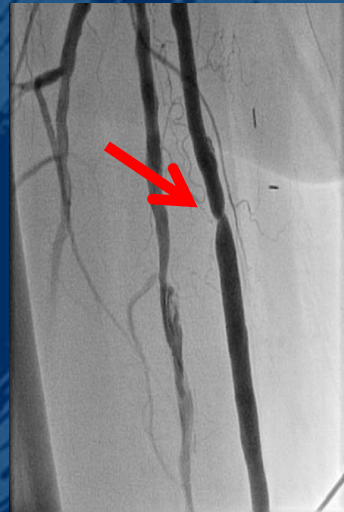

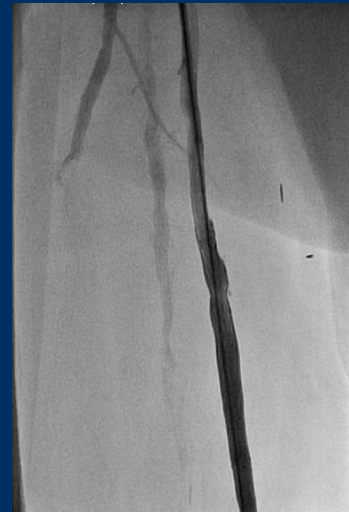# Late rupture of by pass grafting following angioplasty

*69 years old male patient. History of hypertension, dyslipidemia, tabaquism, diabetes, hypothyrodism. Clinical condition: Critical limb ischemia (Fountaine Classification: grade IV).*

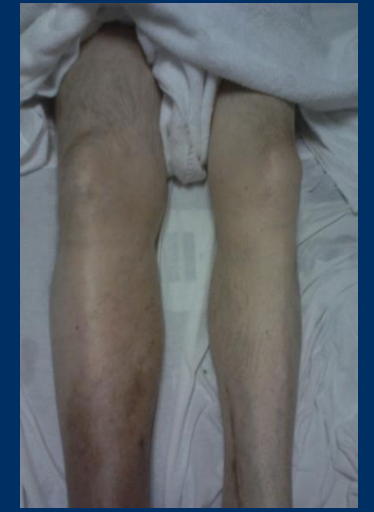*Angiogram showed severe lesion within the venous by pass grafting in right lower limb.*



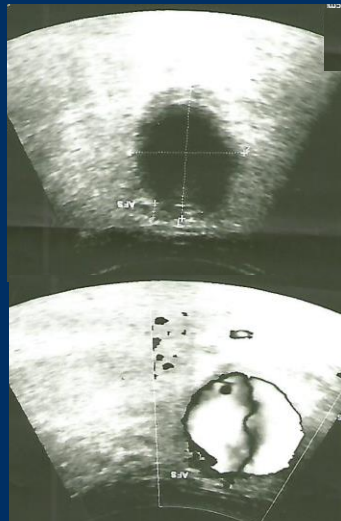
*Treated with self-expanding peripheral stent (7.0 x 60 mm Complete SE Medtronic®). Postdilation with peripheral balloon.*



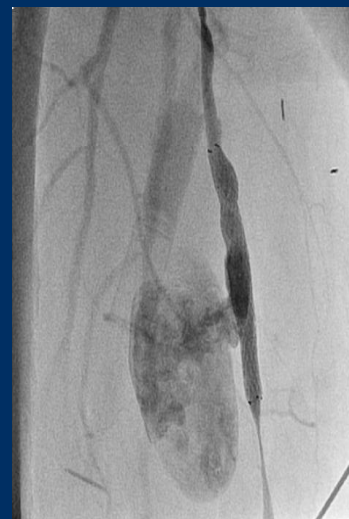*One week later, the patient developed right lower limb edema and pain.*



*Ultrasound revealed pseudo-aneurysm next to the by pass grafting: 4.16 x 3.55 cm. (The “Yin-yang” sign).*



*Angiogram showed pseudo-aneurysm in the proximal third of the bypass grafting.*



*Treated with endoprosthesis. (Viabahn Gore® 7.0 x 150mm). Final result: patent device without filling of the pseudo-aneurysm.*

